


**PRESENTING CLINICAL SIGNS**

**DATE** History: Grade IV/VI left-sided murmur. Pre-anesthetic evaluation (dental). Previously prescribed pimobendan 0.625 mg BID and furosemide 12.5 mg SID as needed. Medications not given regularly.

11/8/22

**ECHOCARDIOGRAPHIC FINDINGS**

2D, M-mode, Doppler study.

**PERFORMED BY:**

Dr. Meredith Swart

There is mild to moderate left atrial dilation. The mitral valve leaflets are thickened and exhibit systolic prolapse. There is Doppler evidence of mitral regurgitation present. There is mild to moderate left ventricular dilation. Left ventricular systolic function is mildly hyperdynamic. The aorta and aortic valve are normal. Right atrial and right ventricular dimensions are normal. The tricuspid valve is normal. The pulmonary artery and pulmonic valve are normal. No pericardial effusion or cardiac masses are seen.

**INTERPRETED BY**

Keith Blass, DVM,  
MS, DACVIM  
(Cardiology)

LA - 21.3 mm  
LVIDd - 21.0 mm  
LVIDs - 12.1 mm  
FS - 42.4%  
LVOT - 1.68 m/s  
RVOT - 0.95 m/s

**PATIENT**

Chico Northcutt

**ASSESSMENT/RECOMMENDATIONS**
**SPECIES**

Degenerative mitral valve disease

Canine

This examination demonstrates regurgitation of blood across Chico's mitral valve resulting from degenerative valve disease. Secondary to his regurgitation, Chico has mild to moderate dilation of both his left atrium and left ventricle, though his left ventricular systolic is well-preserved. Chico's mitral valve disease is still compensated, however, he is at risk for the development of clinical signs secondary to his disease, such as coughing, exercise intolerance, syncope, and labored breathing, therefore, careful monitoring for these signs is recommended.

**BREED**

Maltese

**SEX**

Chico's cardiovascular risk for general anesthesia is mildly to moderately increased based on this exam, therefore, some precautions should be taken in order to minimize this risk. I recommend avoiding the use of alpha-2 agonists, ketamine, and telazol in the anesthetic protocol, as well as reducing the IV fluid rate by 50%. If possible, monitoring of heart rhythm, blood pressure, and pulse oximetry are recommended during the procedure.

MI

**AGE**

Continued use of pimobendan is warranted based on this exam. Continued use of furosemide (1-2 mg/kg BID) would be warranted if Chico has previously experienced clinical signs that resolved with therapy.

10 y

**WEIGHT**

A recheck echocardiogram is recommended in 9 months. Thoracic radiographs are recommended if Chico experiences respiratory clinical signs.

1.74 kg

**HOSPITAL NAME**

Swart Veterinary  
Imaging

**REFERRING VET**

Dr. Swart



**DATE**

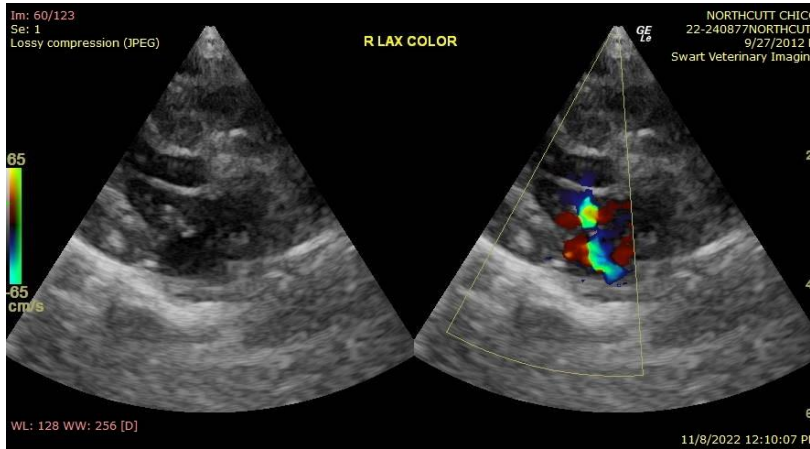
11/8/22

**PERFORMED BY:**

Dr. Meredith Swart

**INTERPRETED BY**

Keith Blass, DVM,  
MS, DACVIM  
(Cardiology)



**PATIENT**

Chico Northcutt

**SPECIES**

Canine

The information and recommendations provided are based on the images presented by the referring veterinarian. No evaluation can be communicated regarding pathology that was not visible in the image/video clips provided.

**BREED**

Maltese

Thank you for this referral. If the clinical or image interpretation does not parallel your findings or if I can be of any further assistance please contact me.

**SEX**

Keith Blass, DVM, MS, DACVIM (Cardiology)

**MI**

KeithBlass@gmail.com  
631-804-5754

**AGE**

10 y

**WEIGHT**

1.74 kg

**HOSPITAL NAME**

Swart Veterinary  
Imaging

**REFERRING VET**

Dr. Swart